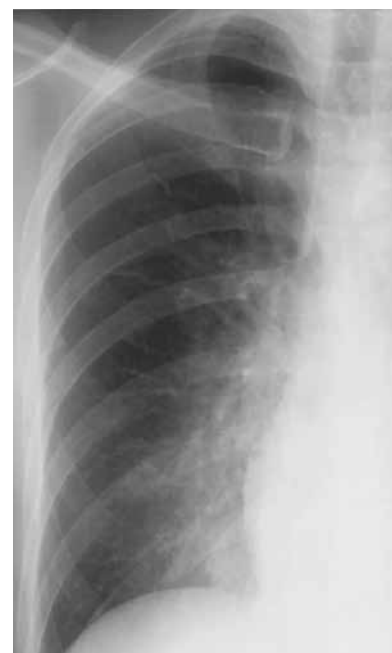

E. Eisenhuber, C. Schäfer-Prokop, H. Prosch, E. Kaindl

# Chest



## Imaging procedures

Approximately 40% of all radiographic examinations are performed to investigate pathologies of the chest. The following imaging modalities are used for diagnostic investigation of the chest:

- Chest X-ray
- Fluoroscopy
- Computed tomography (CT)
- Ultrasonography (US)
- Magnetic resonance imaging (MRI)

### Chest X-ray (heart and lungs)

The chest X-ray still is the initial examination procedure for diseases of the heart and lungs. The film-screen technique has been almost completely replaced by digital detectors in the form of combined image plate systems or digital solid state detectors.

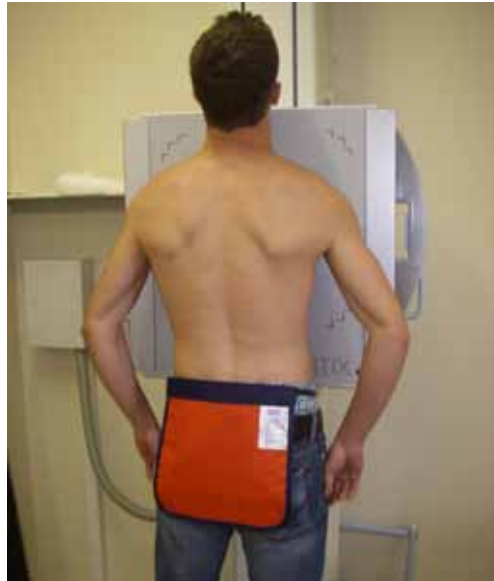The radiation burden of a conventional chest radiograph is low. A chest X-ray in two planes performed under optimal conditions, is associated with a radiation dose of about 0.02 mSv, which amounts to approximately a hundredth of the natural radiation burden per year.

### Chest X-ray in standing position

The chest X-ray is performed in deep inspiration. Posteroanterior and lateral images along the left side are obtained. A focus film distance of 2 meters is used so that magnification of structures due to projection (especially the shadow of the heart) is minimized. Derived from the conventional film-screen technique, the high-kilovoltage technique (about 120 kV) was adopted for the digital procedure in order to minimize the absorption of superimposing ribs. Although several studies have shown that a low kV with no increase in the effective dose provides better contrast of lung parenchyma, this technique has not been widely accepted.

#### Chest X-ray (heart and lungs)

- » Initial investigation
- » low radiation burden



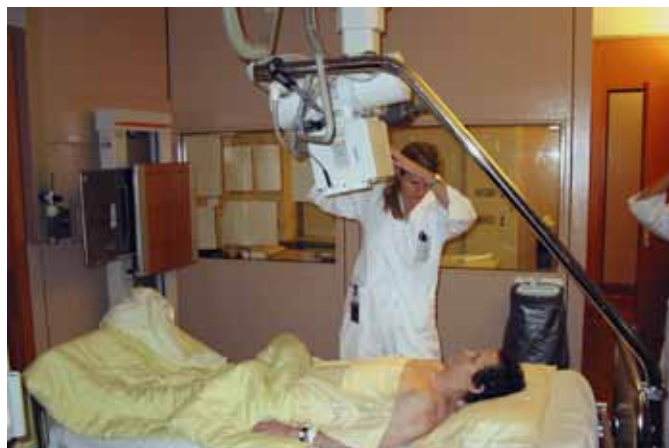Imaging parameters:

- deep inhalation
- posteroanterior/lateral projection
- focus-film distance 2 meters

*Fig. 1: Chest X-ray, posteroanterior, in standing position.*

### Chest X-ray in a supine patient

In patients who are unable to walk, the images are obtained in supine position with the aid of mobile X-ray devices. Anteroposterior images are taken. A lateral image cannot be obtained in supine position. Due to anteroposterior projection and the small focus-film distance of just 1 meter, the heart appears a little enlarged. Furthermore, pleural effusions are distributed along the dorsal chest wall in supine position, and can be detected only from a quantity of about 500 ml onward.



*Fig. 2: Bedside image of the chest in supine position, anteroposterior view (bedside X-ray).*

### Fluoroscopy

In selected cases one performs an additional fluoroscopic investigation. The radiation burden of fluoroscopy depends on the duration of the investigation. It is usually markedly higher than that of a conventional X-ray. Therefore, the procedure is reserved for a small number of indications.

Indications for fluoroscopy are the following:

- assessment of the motion of the diaphragm
- control of pacemaker probes (a free floating probe tip)

### Computed tomography

Computed tomography is the most sensitive examination technique for diagnostic investigation of pulmonary and mediastinal processes. It has a wide spectrum of indications.

**Fluoroscopy:**  
» used very selectively

**CT** → most important additional investigation technique

Important indications are the following:

- solitary pulmonary nodules, consolidations
- diffuse lung disease
- staging of lung tumors
- investigation of mediastinal and pleural pathologies
- CT-guided biopsy of pathological findings
- search for metastases in tumor staging
- search for hidden seats of infection (immunosuppressed persons, patients undergoing chemotherapy, HIV-positive patients)
- pulmonary embolism
- aortic dissection
- bronchiectasis
- chest trauma
- complications in pneumonia
- investigation of ambiguous findings on chest X-rays

The standard for a lung examination of the lung is continuous spiral data acquisition, which is now performed exclusively with multidetector systems.

The investigation is usually conducted in inspiration.

Contrasting of mediastinal vessels by intravenous application of an iodine-containing contrast medium is required to assess the mediastinum.

The radiation load of a CT of the chest may be more than a hundred-fold higher than that of a chest X-ray, depending on the scope of the investigation and the technique used.

All modern multidetector CT devices used today permit investigation of the volume of the entire lung with a slice thickness of 1 mm. Depending on the question being investigated, the acquired datasets are reconstructed twice: once with thin 1-mm slices for coronal and sagittal reconstruction (so-called multiplanar reconstruction or MPR), and thicker axial slices (5 mm slice thickness) which have a better signal-to-noise ratio for diagnostic assessment. Thus, basically any CT of the chest performed nowadays is a so-called high-resolution CT investigation, because it provides thin slices (1 – 1.5 mm) for viewing.

However, the thinner the slice, the more noise the pictures will contain. Therefore, to assess very intricate details of parenchymatous tissue it may be necessary, in exceptional cases, to obtain individual discontinuous 1-mm slices on high-resolution CT using a higher dose.

As the lung is generally a “high-contrast organ” (i. e. there is high contrast between aerated structures and parenchymatous structures), lung parenchyma can generally be assessed well with a low dose as well. Lung screening is also based on this principle. In lung screening one performs a CT with an ultra-low dose in order to identify or rule out a tumor in high-risk patients.

To depict “air trapping” as a sign of obstruction of the small airways or for investigation of bronchomalacia, one may additionally perform an investigation in expiration. This is usually obtained with a much smaller dose.

### **CT-guided biopsy**

CT-guided transthoracic biopsy permits histological investigation of space-occupying lesions in the chest. The examination is usually performed under local anesthesia and is well tolerated by most patients. One complication could be pneumothorax, which is usually small and does not require further treatment. Larger pneumothoraces must be drained with a chest tube.

Indications for CT of the chest

Investigation technique CT of the chest

US → diagnostic investigation of effusion

MRI:  
» selective indications especially the chest wall and the mediastinum

### Ultrasonography

Ultrasonography is used to demonstrate and quantify pleural effusions as well as for optimal setting of the puncture or drainage site for pleural effusions. In cases of pleural empyema, septations can be viewed prior to drainage. While the exact location and spread of a chambered effusion is better seen on CT, intrapleural septations are depicted more clearly on ultrasonography. In supine patients (such as those in the intensive care unit), ultrasonography can also be used to depict a pneumothorax.

### Magnetic resonance tomography

MRI is currently of secondary importance for investigation of pulmonary pathologies. However, important indications for MRI are the following:

- problematic issues in staging lung carcinoma (processes in the chest wall, such as a Pancoast tumor)
- classification of mediastinal tumors (fatty versus cystic versus solid tumor)
- investigation of patients with an iodine allergy

## Normal radiographic anatomy

### Chest wall

The chest wall consists of soft tissues, ribs, and the spine, Muscles – especially the pectoralis major muscle – and the breasts cause symmetrical reduction of radiotransparency on the lower fields of the lung.

The bony skeleton can be roughly assessed even by the high-kilovoltage technique (poorer contrast of bone structures), such as dislocated rib fractures, destruction due to metastasis, or compressed vertebra in the thoracic spine.

Physiologically the ventral cartilaginous portions of ribs tend to calcify with advancing age. This should not be mistaken for intrapulmonary lesions.

### Diaphragm

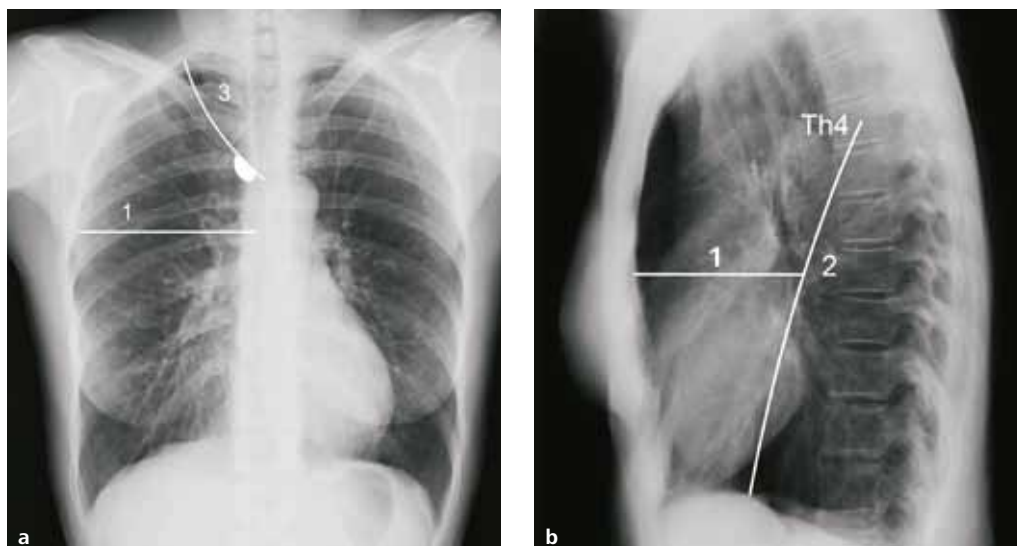
In maximal inspiration, on the posteroanterior image the diaphragm is projected with its apex at the 5th/6th rib in the ventral aspect and the 10th/11th rib in the dorsal aspect. The right dome of the diaphragm will be somewhat higher than the left dome because of the liver.

### Pleura

The pleura consists of a visceral and a parietal layer. The visceral pleura coats the lung in an adherent manner while the parietal pleura forms a coating on the inner cavity of the chest (diaphragmatic/costal/mediastinal pleura).

**Fissures:** Invagination of the visceral pleura causes fissures. The latter form a pleural encasement of three lung lobes on the right side and two lobes on the left side. In a normal individual these fissures between the lobes are seen on the chest X-ray as tender lines only when they are hit tangentially by the radiation beam.

The tender pleural lines of fissures are seen very clearly on CT.

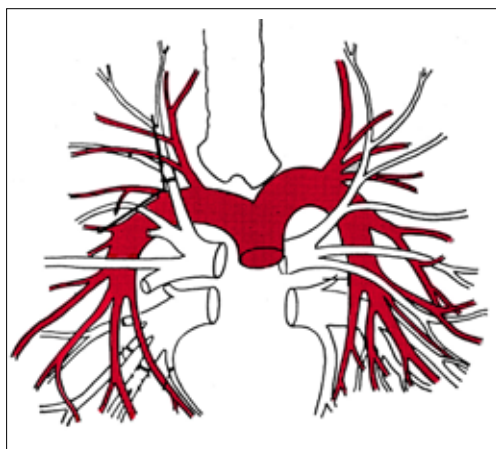


**Fig. 3:** Schematic diagram of fissures on posteroanterior and lateral views. The small fissure (1) which divides the upper and the middle lobe is seen on the posteroanterior (a) and the lateral image (b). Large fissures (2) are normally seen only on the lateral view. In about 0.5 to 1% of cases the investigator will observe an accessory lobe of the azygos vein, caused by a developmental disorder (3). The typical teardrop-shaped entity at the end of the fissure contains the azygos vein; the azygos vein lobe is in its medial aspect.

Fissures

## Vessels

The pulmonary trunk is divided into the right and the left pulmonary artery. The central pulmonary arteries are divided together with the bronchi into lobar, segmental, and subsegmental arteries, and are seen on the X-ray to a distance of about 2 cm from the chest wall.



**Fig. 4:** Schematic diagram of central pulmonary vessels. Pulmonary arteries (red) are more dominant than pulmonary veins (white). The two are not early distinguished from one another on the chest X-ray. Pulmonary arteries and veins can be distinguished only by their direction of flow at the level of the hilum.

### Pulmonary vessels on the chest X-ray:

On a conventional lung X-ray of a healthy person, the visible parenchyma of the lung consists of pulmonary arteries and veins. The hilum of the lung in a healthy person also consists almost entirely of pulmonary vessels. Lymph nodes become visible only when they are significantly enlarged. Physiologically the left hilum is about 1 to 2 cm higher than the right hilum. If at all, arteries and veins can be distinguished only in regions close to the atrium on the basis of their different pathways (pulmonary veins course rather horizontally towards the left atrium while pulmonary arteries run in the radial aspect from the hilum).

In a healthy person the diameter of veins mainly depends on hydrostatic pressure. In standing position the veins in the lower lung fields are of greater diameter than those in the upper fields. The diameters are balanced in supine position.

On the chest X-ray of a healthy person one only sees pulmonary vessels → no normal lung tissue is seen

Vascular pattern in a healthy lung

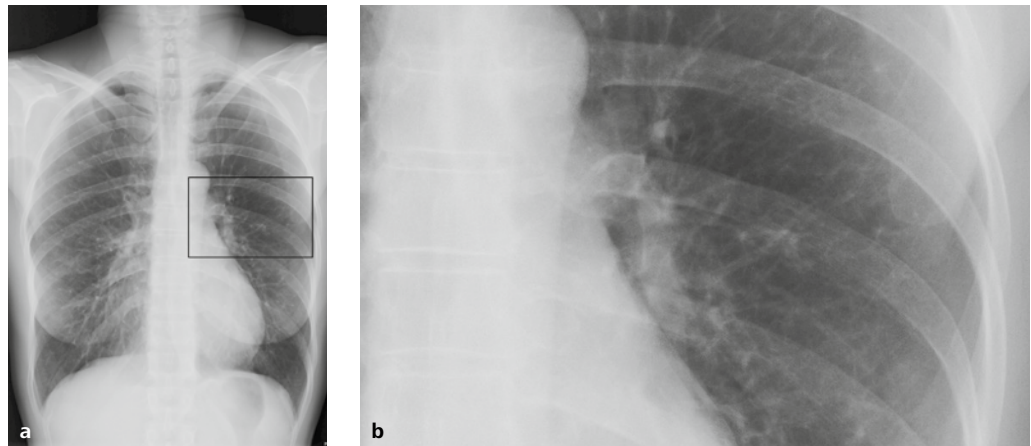
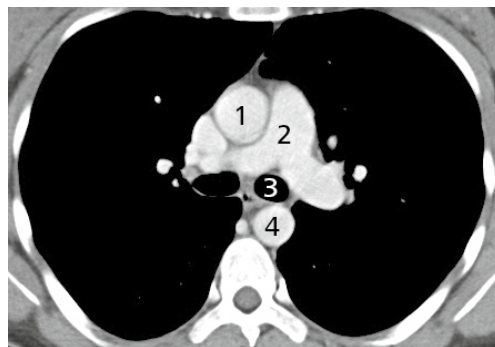


Fig. 5: Pulmonary vessels: normal chest X-ray (a), detail from Figure a, vascular pattern, the left hilum (b).

### Pulmonary vessels on computed tomography

Central as well as peripheral arteries and veins can be clearly differentiated from each other on contrast-assisted chest CT because of their different anatomical pathways (artery accompanies the bronchus). In a healthy person, vascular structures can be identified until about 1 to 2 cm in the subpleural aspect (see **Structure of the lung** below).

Central vessels



- 1 ascending aorta
- 2 pulmonary trunk
- 3 left main bronchus
- 4 descending aorta

Fig. 6: Section from a chest CT – central vessels, cut through the pulmonary trunk and the pulmonary bifurcation.

### Structure of the lung

The trachea starts at the lower margin of the cricoid cartilage. There is no anatomical margin between the cervical and the intrathoracic portion of the trachea.

At the level of the 4th/5th thoracic vertebra, the trachea is divided into the two main bronchi, which branch out in dichotomous fashion into lobar bronchi and segmental bronchi.

Tracheo-/bronchial tree

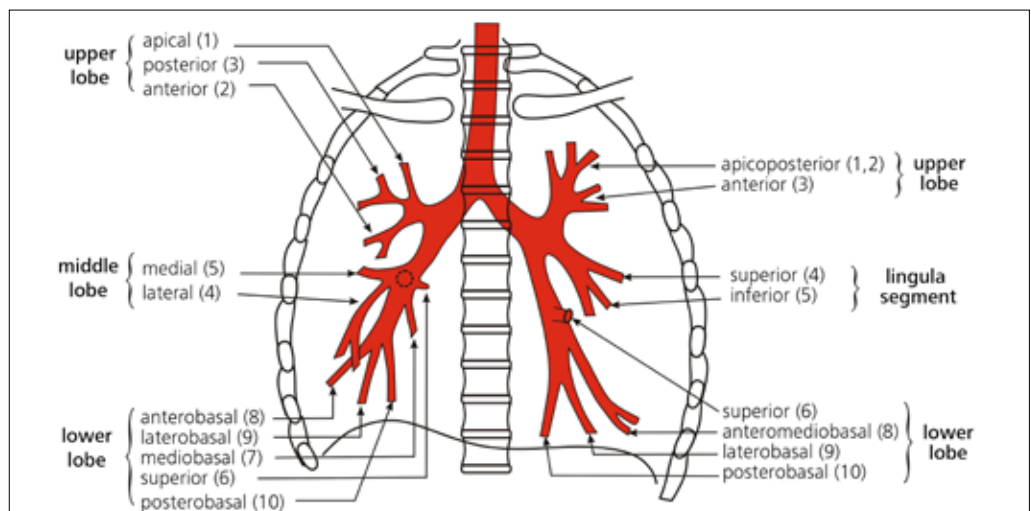
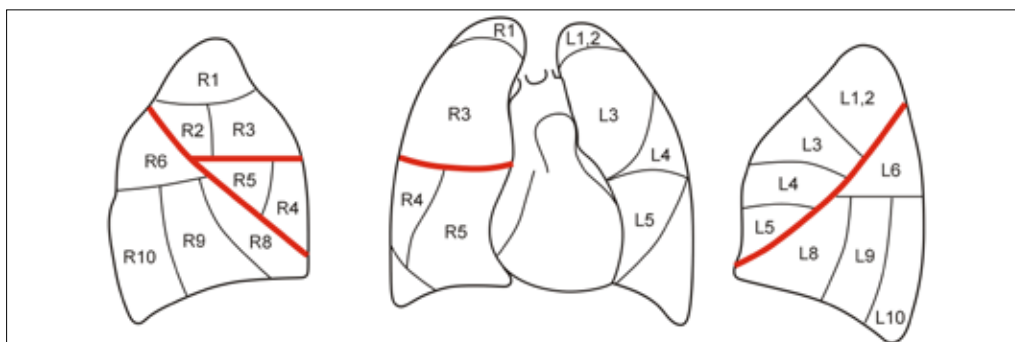


Fig. 7: Schematic diagram of the distribution of the bronchial tree. The right lung has three lobes and ten segments. The left lung has only two lobes and eight segments. The lingula is a part of the upper lobe.

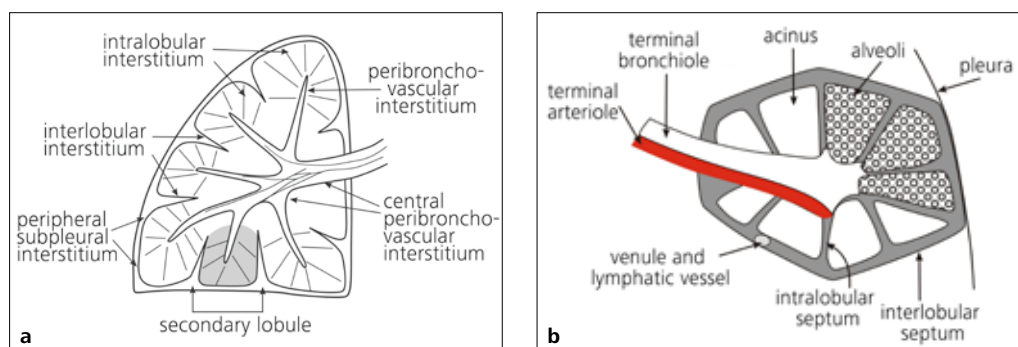


**Fig. 8:** Schematic diagram of the segments of the lung (R: right, L: left). Note: on the posteroanterior view the upper and lower lobes, and the lower and middle lobes are projected on each other. On the lateral view the right and the left lung are projected on each other. Anatomical features can be assessed on the chest X-ray only by viewing both planes.

The structure of the lung is determined by the distribution of the bronchial tree. A distinction is made between lobes, segments and subsegments, and the secondary pulmonary lobule which is the smallest functional unit.

While the lobes are divided by the pleura, the segments, subsegments and secondary lobules are divided by connective tissue (interstitium). A distinction is made between various components of the pulmonary interstitium, which should be viewed as a mutually interlocking supportive connective tissue framework of lung parenchyma:

- the central **peribronchovascular** interstitium;
- the peripheral **subpleural** interstitium envelops the lung and forms the interlobular septa;
- the **intra-lobular** interstitium forms a network around the alveoli and a connection between central and peripheral interstitial tissue.



**Fig. 9:** Schematic diagram of the pulmonary interstitium (a) and the secondary lobule (b). The secondary lobule consists of about 12 acini (on average) with a diameter of 6 to 8 mm, which contains as many as 4,000 alveoli. An acinus is defined as that part of lung parenchyma which lies distal to a terminal bronchiole and is supplied by a respiratory bronchiole.

The secondary lobule is the smallest functional unit of the lung. Its boundaries are marked by connective tissue septa. It is polygonal in shape and its diameter is 1 to 1.5 cm. The terminal bronchiole, the pulmonary artery and its branches (terminal arterioles) are in the central aspect. Veins and lymphatic vessels course within the connective tissue septa.

### Structure of the lung on the chest X-ray

On the conventional radiograph the trachea is in middle position. It is seen as an air lucency measuring about 2 cm in width. The cartilaginous rings of the trachea and the central bronchi may calcify with advancing age and then become visible on the radiograph.

The bronchi in a healthy person are seen only in the central portions of the bronchial tree. Large branches of the bronchi close to the hilum may – when they are hit tangentially by the X-ray beam – be seen as radiolucent streaks with mild linear shadows at their margins. On orthograde images one sees mild circular structures with a central lucency. Further peripherally, the structures of the interstitium cannot be seen in a healthy person.

Lung segments

Interstitium

Central bronchus

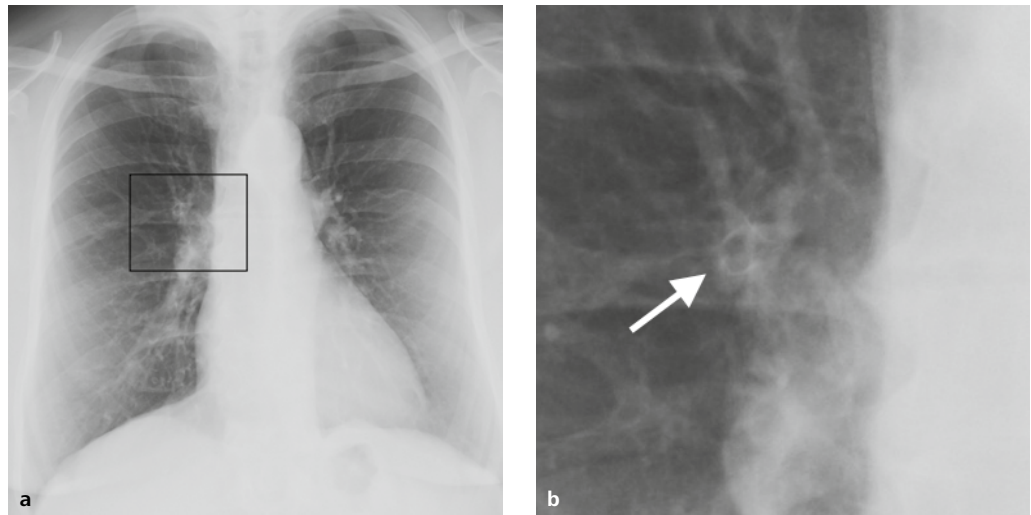


Fig. 10: Lung, posteroanterior view (a), detail of the picture showing the mediastinum, trachea, and central bronchi. The bronchus has been hit by the beam in orthrograde fashion (arrow) (b).

**Structure of the lung on CT**

On a standard CT (slice thickness of 5 to 8 mm) the bronchi are seen to the 4th order. On HRCT (slice thickness of 1 mm) they can be identified to the 8th order.

The visibility of bronchial structures in the peripheral aspect of the lung (<2 cm subpleural) is a sign of pathological thickening of the bronchial wall or ectasia of the small airways.

Branches of the bronchi on CT

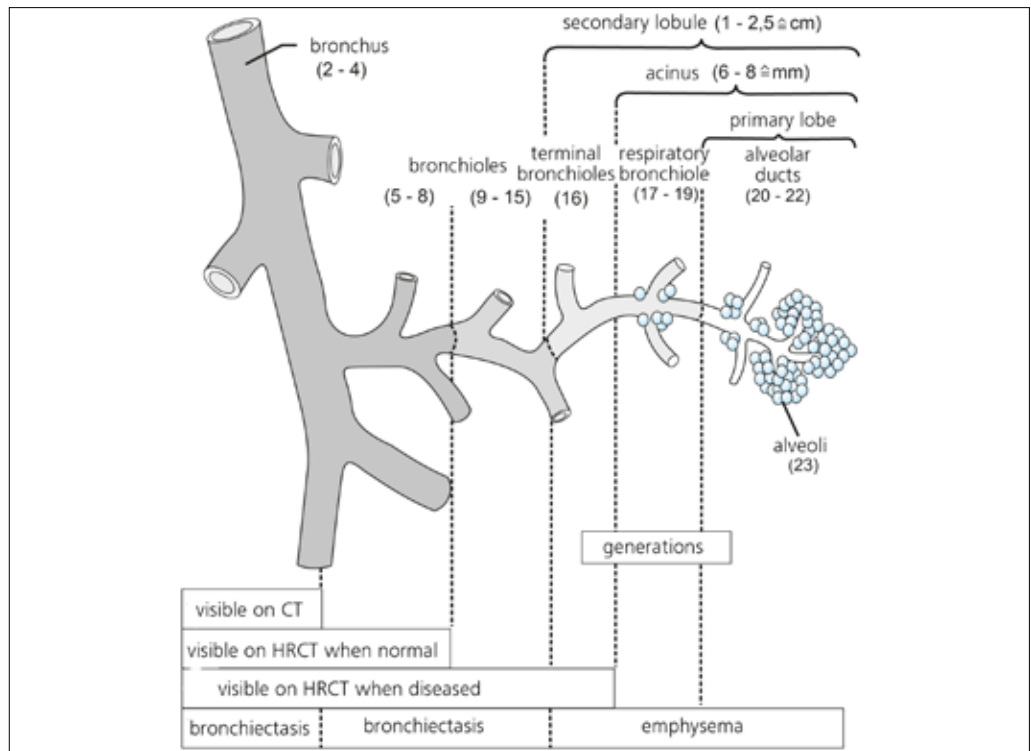


Fig. 11: Schematic diagram of the bronchial tree showing the limits of spatial resolution on CT.

CT – central bronchi

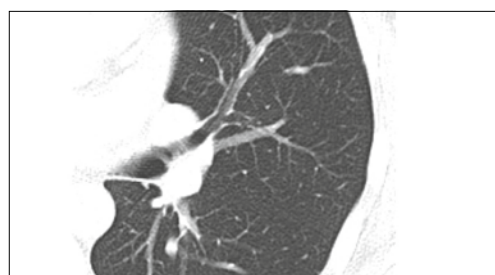

Fig. 12: CT – detail – central bronchi