

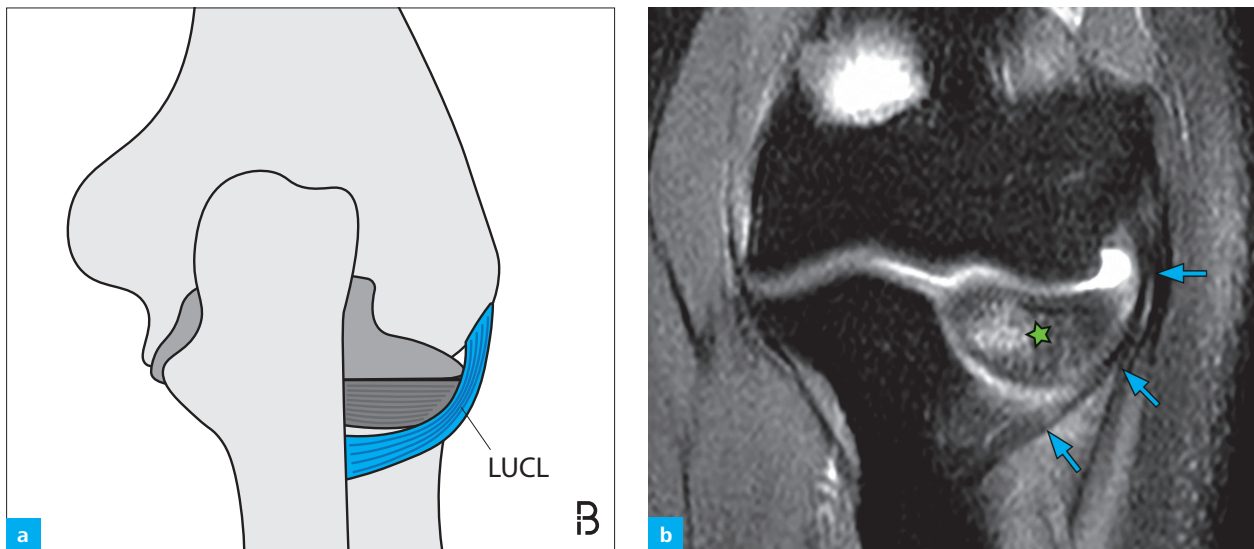Fig. 4: (a) Schematic posterior view of the LUCL (blue) running posteriorly around the radial head and inserting at the tubercle of the supinator crest of the ulna. (b) Coronal intermediate weighted MR image with fat suppression in a 30-year-old woman after falling on her outstretched hand. As the elbow is not fully extended, the course of the normal LUCL (arrows) can be clearly depicted as it runs around the posterior portion of the radial head (asterisk). Note the presence of bone marrow edema within the radial head.

MR Imaging of Acute Ligament Injuries

MRI evaluation of the collateral ligaments of the elbow should be performed with the elbow in full extension. Although the course of certain ligaments such as the LUCL may not be identified on one single image in a standard plane, following the ligaments on consecutive slices is simple. However, imaging patients after an acute injury to the elbow can be challenging, as joint extension may be limited and motion artifacts related to pain and discomfort occur.

As high-quality three-dimensional isotropic fast spin-echo sequences are available for the MR evaluation of joints, the incorporation of a 3D-sequence into the routine elbow protocol may be beneficial. Particularly in patients who are not able to fully extend the elbow, secondary reformations can be helpful for anatomic orientation.²¹ Furthermore, a 20° posterior coronal oblique plane has been shown to best visualize the LUCL on MRI (Fig. 5).²²

Instead of acquiring dedicated oblique coronal 2D-sequences, this particular imaging plane can also easily be created with the multiplanar reformation (MPR) tools included in the picture archiving and communicating system (PACS).

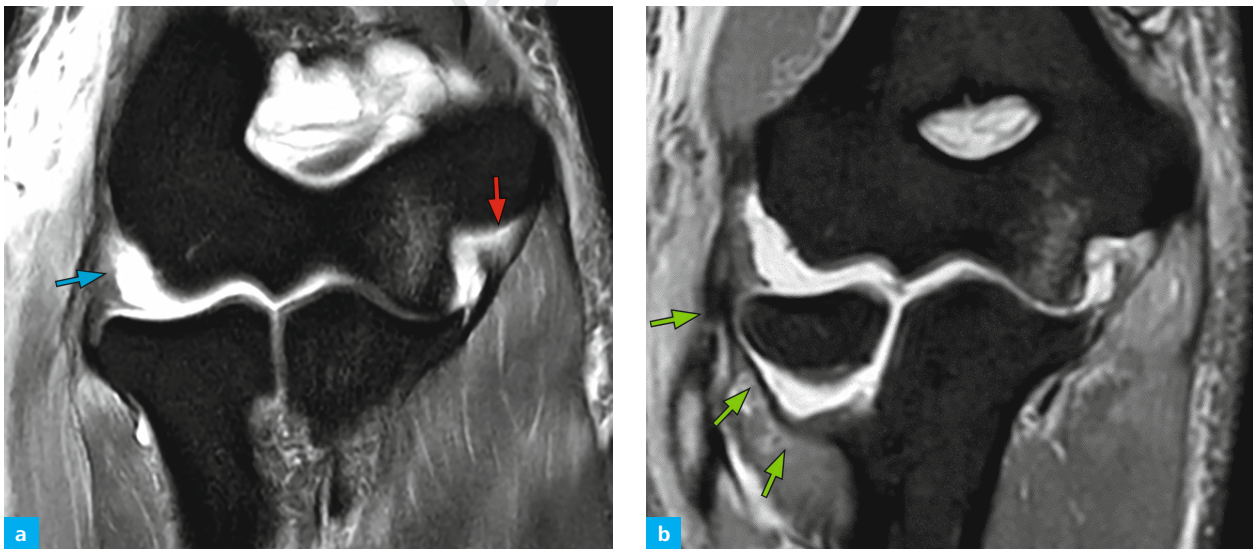


Fig. 5: 28-year-old male after elbow dislocation. (a) 2D intermediate weighted, fat-suppressed MR image in the standard coronal plane shows the proximal avulsion of the LUCL (blue arrow). Note that there is also a partial tear at the origin of the anterior band of the UCL (red arrow). (b) On a corresponding 20° posterior oblique reconstruction from an isotropic 3D intermediate weighted sequence, the entire course of the LUCL (green arrows) can be appreciated on a single image.

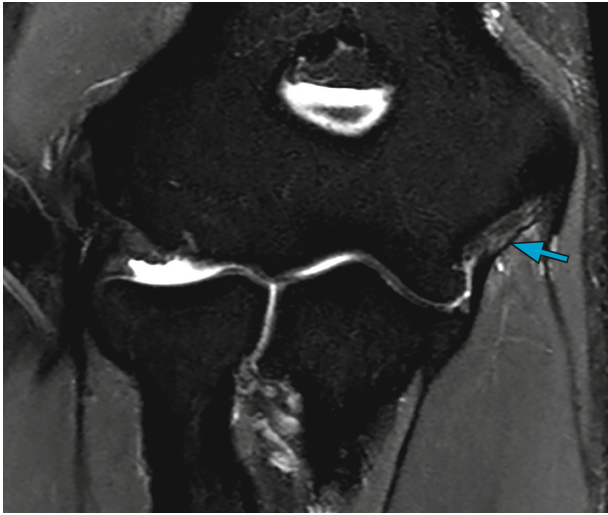


Fig. 6: Coronal intermediate weighted MR image with fat suppression in a young and healthy volunteer. Note the relatively high signal intensity and striation of the proximal UCL (arrow), which is a normal finding.

Usually, normal ligaments appear with low signal intensity on all pulse sequences, but a striated appearance has also been described in young and healthy volunteers in a majority of cases for the UCL and also for the RCL (Fig. 6).^{23,24}

As in general, ligament injuries of the elbow can be classified as either sprains, partial tears or complete tears.²⁵ A ligament sprain can be diagnosed when there is alteration of ligament morphology in the absence of discontinuity and increased signal on T1- or T2-weighted MR images (Fig. 7a).

However, it has been described that 10%–15% of normal collateral ligaments may show high signal intensity, which should not be mistaken for a ligament injury.²³ A partial tear can be diagnosed if there is an area of focal discontinuity of the ligament fibers with residual intact fibers and surrounding edema (Fig. 7b).

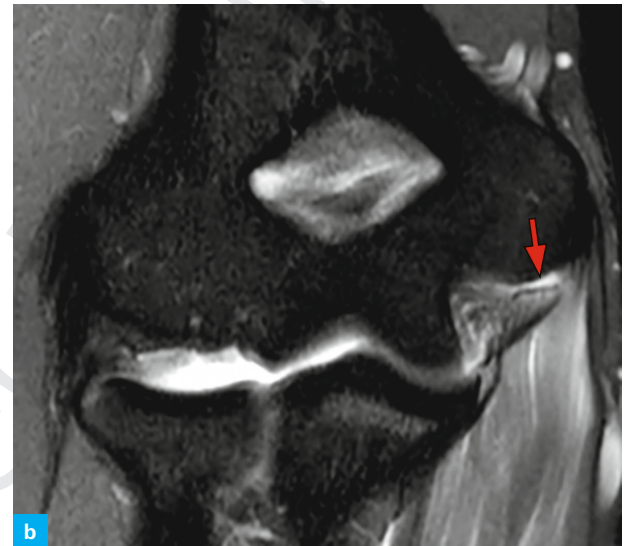
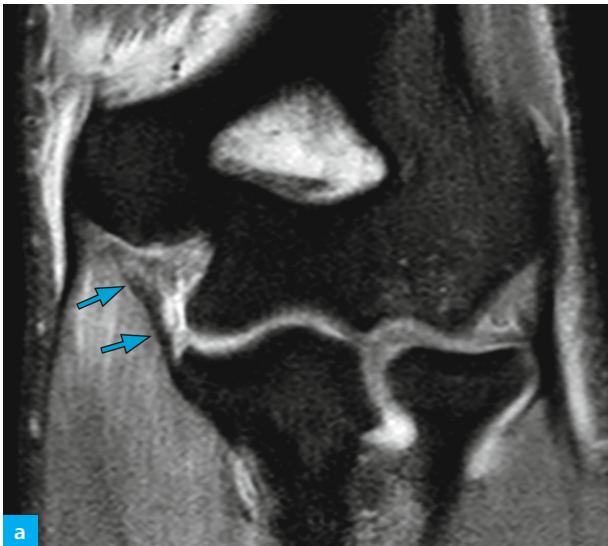


Fig. 7: Ligament injuries of different severity shown on coronal intermediate weighted fat-suppressed MR images in two different patients. (a) UCL sprain of the left elbow with slightly increased signal within the ligament and surrounding edema, without fiber discontinuity (blue arrows). (b) Partial tear (red arrow) of the proximal UCL fibers of the right elbow, with a small tendon defect that is isointense to fluid.

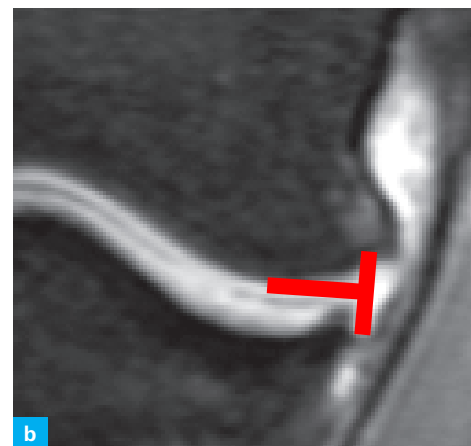
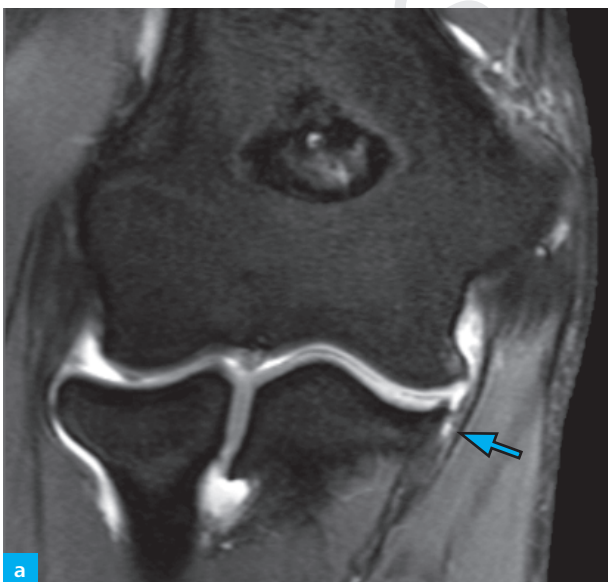

Fig. 8: Distal injury of the UCL at its insertion (arrow) depicted on a coronal intermediate weighted, fat-saturated MRI. (b) Magnified part of the same image shows the letter "T" that is only visible if the distal UCL is torn.

Further, in cases of a distal tear at the insertion of the UCL a positive T-sign can be seen on coronal MR images at the expected insertion of the ligament at the sublime tubercle of the ulna. (Fig. 8). With a positive T-sign joint fluid (or contrast media in patients with MR arthrography) extends distal to the articular cartilage. However, in older patients a false positive T-sign may be present due to ligament laxity. Also T-sign may be seen without the presence of a ligament re-tear in postoperative patients after UCL reconstruction.

On MRI, differentiation between ligament sprains and partial tears may be challenging. According to the literature, standard MRI shows low accuracy in the detection of partial tears of the elbow ligaments (sensitivity: 14%) which is contrary to the excellent visualization of the collateral ligaments with modern high-field MR scanners.²⁶ The observations made mainly rely on the detection of partial undersurface tears in repetitive injury to the UCL in overhead throwing athletes. Additionally, in this particular patient group MR arthrography has been shown to be superior to standard MRI.

Partial tears in a non-athlete group are almost always treated conservatively, therefore well-designed studies with a sufficient standard of reference on the accuracy of standard MRI for the detection of sprains and partial tears are still lacking.^{27,28} Full thickness tears of the collateral ligaments appear as discontinuity of the ligament fibers or wavy ill-defined ligament morphology, and abnormal extravasation of joint fluid or intraarticular contrast media in arthrographic studies (Fig. 9).

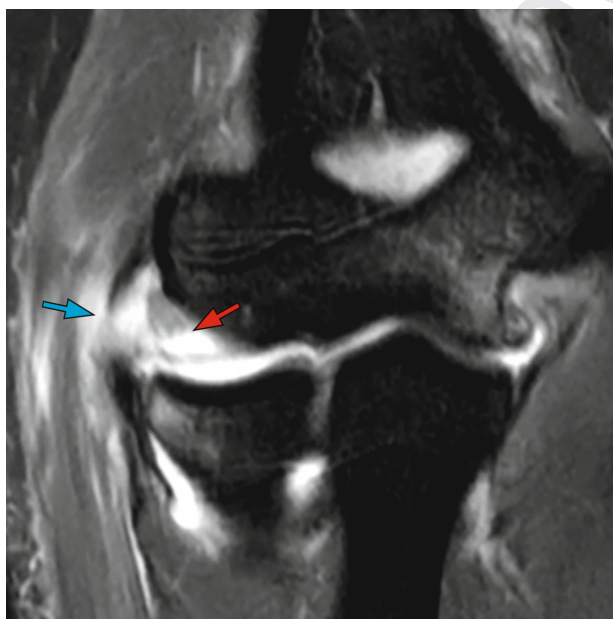


Fig. 9: Coronal intermediate weighted MR image with fat suppression of a full thickness tear of the RCL. Complete discontinuity of ligament fibers with fluid-filled gap (red arrow) and extravasation of joint fluid (blue arrow). Note that there is also a strain of the UCL.

One study in cadaveric specimens reported a sensitivity of 88% and a specificity of 45%–75% for intermediate weighted coronal MR sequences in the diagnosis of LUCL full thickness tears.²⁹ The authors also described a sensitivity of 55%–88% and a specificity of 80%–100% for UCL tears. However, a study on 3T MRI with arthroscopy as a reference standard published recently showed that standard MRI is 100% sensitive and 89% specific for the detection of full thickness UCL tears, 70% sensitive and 100% specific for full thickness RCL tears.³⁰ MR arthrography has been reported to be 100% sensitive and specific for the detection of collateral ligament tears at the elbow.³⁰ In conclusion, standard MR imaging has been shown to be highly accurate in the detection of full thickness tears of the collateral ligaments of the elbow. In unclear cases, MR arthrography may be of additional value. On the other hand, there is still lack of evidence for MRI use in the diagnosis of ligament sprains and partial tears. However, due to the constant improvement in image quality in recent years, standard MRI can be considered a valuable tool in the evaluation of acute injury to the collateral ligaments of the elbow.

Elbow Instability

Classification of Elbow Instability

Elbow dislocations can be classified in many different ways. Classification is possible according to the temporal aspect of the injury (acute, chronic, or recurrent), the articulations involved, or the displacement direction (valgus, varus, anterior, posterior, posterolateral, and rotatory instability).³¹

A very common and reasonable classification is the discrimination between simple and complex elbow dislocations. The main distinctive feature is the presence or absence of a fracture. Simple dislocations are defined as soft tissue injuries, whereas complex dislocations include osseous fractures or disruption. They are associated with a fracture in approximately 25%–50% of cases.^{1,32} The most severe complex elbow dislocation is the so-called terrible triad injury, a dislocation with concomitant fracture of the radial head and the coronoid process associated with an RCL tear (Table 1).³³ For the subsequent treatment of fractures in complex elbow dislocations, these patients typically are referred to computed tomography (CT) while the soft tissue injury in simple dislocation can be better visualized with ultrasound or MRI.